

## Research Article

# Injury-Induced Acute Paronychia in Healthcare Professionals: A Single-Centre Study

 **Fatih Ceran**,<sup>1</sup>  **Emin Kapi**,<sup>2</sup>  **Mehmet Dokur**<sup>3</sup>

<sup>1</sup>Department of Plastic, Reconstructive and Aesthetic Surgery, Biruni University Medical Faculty, Istanbul, Türkiye

<sup>2</sup>Department of Plastic, Reconstructive and Aesthetic Surgery, University of Health Sciences Adana City Training and Research Hospital, Adana, Türkiye

<sup>3</sup>Department of Emergency Medicine, Biruni University Medical Faculty, Istanbul, Türkiye

### Abstract

**Objectives:** Hand infections are important factors affecting human health. The issue of work accidents has become very important with the increase in work ethics and culture. Work accidents also affect healthcare professionals. The aim of the present study is a detailed analysis of healthcare workers who develop acute paronychia in the workplace.

**Methods:** The study included twenty healthcare workers who developed acute paronychia as a result of workplace trauma between 2017 and 2021. Paronychia occurred in all patients following needle or scalpel sticking at work.

**Results:** The patients recovered on the 5th day after treatment. One patient underwent surgical drainage. There was no recurrence in long-term follow-up. Acute paronychia was statistically significantly more common in the female patient group (n=16) and mostly occurred due to needle sticking (n=17).

**Conclusion:** In this study, it has been put forward for the first time in the literature that acute paronychia may occur due to trauma occurring in the workplace among healthcare workers.

**Keywords:** Flexor tendon, injury, reconstruction

**Cite This Article:** Ceran F, Kapi E, Dokur M. Injury-Induced Acute Paronychia in Healthcare Professionals: A Single-Centre Study. EJMI 2024;8(2):119–122.

Fingertip infections are the most common hand and upper-extremity infections.<sup>[1,2]</sup> Patients who develop fingertip infections are mostly admitted to emergency services, hand surgery, dermatology, and primary care physicians. Early diagnosis and treatment are necessary to prevent morbidity and workforce losses.<sup>[3]</sup>

Infections that occur under the paronychium or eponychium are called *paronychia*. Paronychia is usually caused by inoculation of *Staphylococcus aureus* (most common), *Streptococcus pyogenes*, or Gram-negative rods following minor trauma or contamination with polymicrobial bacteria. Paronychia is the most common infection of the hand.

<sup>[2,4]</sup> The diagnosis of paronychia is made through history and examination; it typically presents as painful swelling and erythema in the paronychium and/or eponychium.<sup>[5-8]</sup>

Healthcare workers may be exposed to hand or finger traumas during work, leading to the loss of labor productivity, a decrease in workers' quality of life, and the potential deterioration of the delivery of health services.

This study, which is the first of its kind in the literature, aims to retrospectively evaluate healthcare workers who report acute paronychia during work and to develop various preventive strategies.

**Address for correspondence:** Fatih Ceran, MD. Department of Plastic, Reconstructive and Aesthetic Surgery, Biruni University Medical Faculty, Istanbul, Türkiye

**Phone:** +90 532 421 02 96 **E-mail:** fatihcrn@hotmail.com

**Submitted Date:** January 11, 2023 **Revision Date:** March 03, 2023 **Accepted Date:** March 08, 2023 **Available Online Date:** July 19, 2024

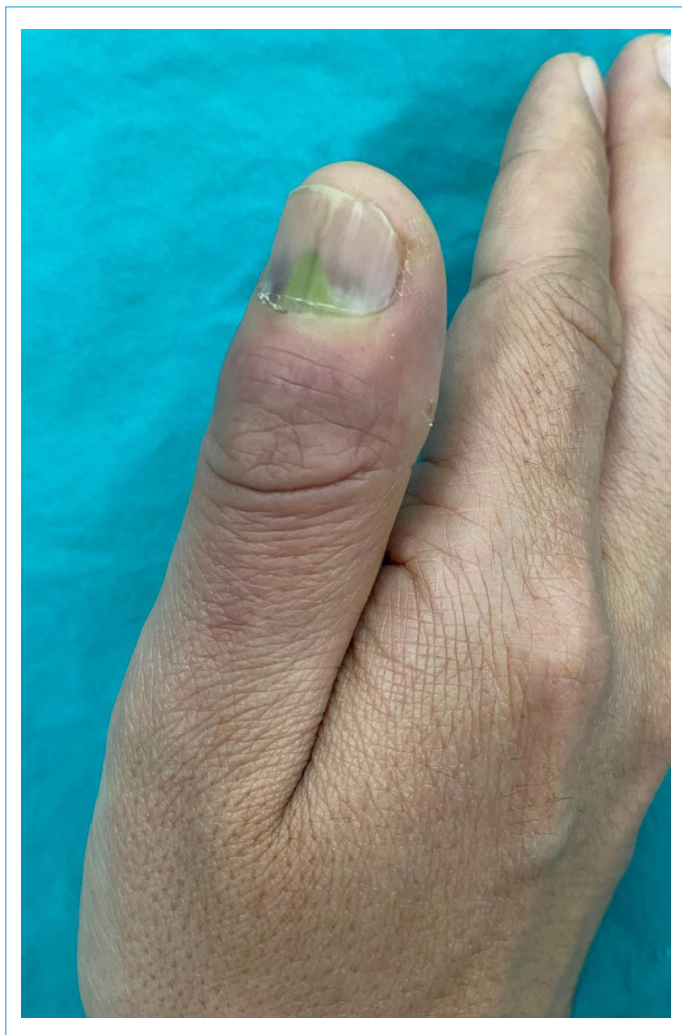
©Copyright 2024 by Eurasian Journal of Medicine and Investigation - Available online at [www.ejmi.org](http://www.ejmi.org)

**OPEN ACCESS** This work is licensed under a Creative Commons Attribution-NonCommercial 4.0 International License.



## Methods

This study was approved by the Ethics Committee (No. 2322). Twenty patients (four male, sixteen female) who developed acute paronychia after finger trauma at work between 2017 and 2023 were included in the study. The mean age of the patients was 22,35 years (range: 19–28). None of the patients had any accompanying disease. Fifteen patients were emergency department nurses, three were emergency department physicians, and two were inpatient ward nurses. Paronychia occurred in all patients following needle or scalpel stick injuries at work. Abscess formation was present in one patient, who received a preliminary diagnosis of malignant melanoma at consultation (Fig. 1, Table 1). Topical fusidic acid was applied following incision and drainage. All patients received 1,000 mg oral amoxicillin/clavulanate twice daily and topical fusidic acid twice daily for one week. Informed consent was obtained from all patients.



**Figure 1.** A patient with acute paronychia due to needle sticking injury and previously diagnosed with malignant melanoma.

## Statistical Analysis

The one-sample z-test was performed to assess whether the hypothesized population rates with equal proportions in each component differed significantly from the observed sample rates. All tests were two-tailed, and  $p < .05$  was considered statistically significant.

## Results

Recovery was observed on the 5th day after the treatment, and there was no recurrence over the following days. The patients returned to work on the 10th day after the treatment. The majority of the patients were female, and the difference between genders was significant ( $n=12$ ;  $p < 0.05$ ).

The majority of the patients were nurses ( $n=17$ ;  $p < 0.05$ ), and emergency department nurses were significantly more affected ( $n=15$ ;  $p < 0.05$ ). Statistically, paronychia was more common in people working in emergency departments ( $n=18$ ;  $p < 0.05$ ).

The most affected finger was the middle finger ( $n=15$ ), followed by the thumb ( $n=3$ ) and index finger ( $n=2$ ) ( $p < 0.05$ ).

Infection was most common after needle sticking ( $n=17$ ); all of the patients presenting with this type of injury were nurses ( $p < 0.05$ ). This was followed by scalpel pricking; all of the patients presenting with scalpel pricks were physicians ( $n=3$ ).

Abscess formation occurred in only one patient, and it was not statistically significant ( $p > 0.05$ ). All patients received 1,000 mg oral amoxicillin/clavulanate and topical fusidic acid treatment ( $n=20$ ; see Table 1).

## Discussion

Physical, chemical, mechanical, biological, ergonomic, or psychosocial hazards pose dangers to employees' health and may directly or indirectly harm them. Healthcare workers, professionals who possess the valuable experience and skills needed to promote the recovery and maintenance of human health, are constantly exposed to infectious waste, cutting implements, and other hazardous factors found in healthcare facilities. Therefore, it is imperative to develop a strong safety culture in which all employees, including patient care professionals and managers, take responsibility for themselves, their colleagues, patients, and their families.<sup>9</sup> According to CDC data, the healthcare system in the United States employs more than 18 million workers, and women represent approximately 80% of the healthcare workforce. Healthcare workers may face a wide variety of hazards while at work, including injuries with sharp objects, exposure to chemicals and drugs, back injuries, latex allergies, violence, and stress.<sup>[10]</sup>

**Table 1.** Sociodemographic and medical characteristics of the patients

Patient	Age	Gender	Profession	Location	Etiology	Treatment
1	22	F	Emergency nurse	Middle finger	Needle stick injury	Antibiotherapy
2	19	F	Emergency nurse	Middle finger	Needle stick injury	Antibiotherapy
3	20	F	Emergency nurse	Middle finger	Needle stick injury	Antibiotherapy
4	27	M	Emergency physician	Middle finger	Surgical blade injury	Antibiotherapy
5	22	F	Emergency nurse	Middle finger	Needle stick injury	Antibiotherapy
6	19	F	Emergency nurse	Index finger	Needle stick injury	Antibiotherapy
7	20	F	Emergency nurse	Index finger	Needle stick injury	Antibiotherapy
8	21	M	Emergency nurse	Thumb	Needle stick injury	Antibiotherapy + Drainage
9	25	M	Emergency physician	Middle finger	Surgical blade injury	Antibiotherapy
10	28	M	Emergency physician	Middle finger	Surgical blade injury	Antibiotherapy
11	22	F	Inpatient service nurse	Middle finger	Needle stick injury	Antibiotherapy
12	20	F	Inpatient service nurse	Thumb	Needle stick injury	Antibiotherapy
13	22	F	Emergency nurse	Middle finger	Needle stick injury	Antibiotherapy
14	23	F	Emergency nurse	Middle finger	Needle stick injury	Antibiotherapy
15	25	F	Emergency nurse	Middle finger	Needle stick injury	Antibiotherapy
16	22	F	Emergency nurse	Middle finger	Needle stick injury	Antibiotherapy
17	28	F	Emergency nurse	Middle finger	Needle stick injury	Antibiotherapy
18	21	F	Emergency nurse	Thumb	Needle stick injury	Antibiotherapy
19	20	F	Emergency nurse	Middle finger	Needle stick injury	Antibiotherapy
20	21	F	Emergency nurse	Middle finger	Needle stick injury	Antibiotherapy

F: Female; M: Male.

Injuries with sharp objects pose a risk for bacterial, viral, fungal, or sometimes parasitic infections. Healthcare workers are exposed to a high risk of contact with infectious agents due to the nature of their jobs.<sup>[9,10]</sup> Paronychia is an infection of the parts of the nail system called the paronychium or eponychium and often occurs due to bacterial inoculation following microtraumas.<sup>1-4</sup> No study examining paronychia in healthcare workers could be found by the authors in the literature.<sup>[10]</sup> Thus, this study evaluating 20 healthcare workers presenting with acute paronychia represents a novel research contribution.

Physical examination of patients with acute paronychia reveals pain, erythema, and swelling. In advanced cases, abscess formation may occur.<sup>[11]</sup> Abscess formation was present in only one patient in the study. This may be due to the fact that healthcare professionals have a well-developed ability to recognize abnormal conditions in patients and themselves. The reason for the delay in the treatment of the patient with abscess formation was a preliminary diagnosis of malignant melanoma. Studies have reported that malignant melanoma in the nail bed can be confused with paronychia.<sup>[12]</sup>

It is noteworthy that the majority of the cases in this study were physicians and nurses working in emergency departments. This can be attributed to the hectic work environment in these departments, high patient density, the need

for rapid action, and long working hours. Another reason is that personal protective equipment, such as gloves, used by emergency department employees is ineffective against piercing and cutting objects. This study shows that more effective equipment should be developed to protect healthcare workers in emergency departments from sharp objects, such as needles and scalpels. The mean age of the patients in this study was 22,35 years, indicating a lack of experience. Of course, experience is a crucial factor in protecting healthcare professionals from occupational accidents; however, it is imperative to organize regular training to prevent these accidents.

Hand and upper-extremity injuries and subsequent infections occur frequently. During hand-infection examinations, the fingertips have been found to be the most frequently involved body parts.<sup>[1,2,13-15]</sup> The middle finger is exposed to trauma more frequently than others.<sup>16</sup> In our study, the most affected finger was the middle finger, which is consistent with the literature.

Oral and topical antibiotic treatment is sufficient in cases of early paronychia without abscess development. In a study by Wollina,<sup>[17]</sup> it was reported that topical fusidic acid was more effective than topical gentamicin. In our study, topical fusidic acid was used in all patients. Oral antibiotics should cover Gram-negative bacteria, anaerobic bacteria, and Gram-positive cocci in patients exposed to oral flora

or animal bites.<sup>[18,19]</sup> In the present study, oral amoxicillin/clavulanate treatment was started in all patients. Only one patient required drainage.

## Conclusion

This study explicated in detail that acute paronychia might develop due to occupational accidents in healthcare workers, which represents a novel contribution to the literature. Key implications include that it is essential to provide health workers with appropriate training on occupational accidents and that gloves and more effective personal protective equipment should be developed for employees working in emergency departments.

## Disclosures

**Ethics Committee Approval:** This study was approved by the Clinical Research Ethics Committee of Adana City Training and Research Hospital (Decision Date and Permission Number: 15.12.2023/2322).

**Peer-review:** Externally peer-reviewed.

**Conflict of Interest:** None declared.

**Authorship Contributions:** Concept – F.C., E.K., E.K.; Design – F.C., E.K., M.K.; Supervision – F.C., E.K.; Materials – F.C., E.K.; Data collection &/or processing – F.C., E.K., M.D.; Analysis and/or interpretation – F.C., M.D.; Literature search – M.D., E.K.; Writing – F.C., M.D., E.K.; Critical review – F.C., M.D., E.K.

## References

- Jebson P. Infections of the fingertip. Paronychias and felons. *Hand Clin.* 1998;14(4):547–55.
- Rabarin F, Jeudy J, Cesari B, et al. Acute finger-tip infection: Management and treatment. A 103-case series. *Orthop Traumatol Surg Res.* 2017;103(6):933–6.
- Fowler J, Ilyas A. Epidemiology of adult acute hand infections at an urban medical center. *J Hand Surg Am.* 2013;38(6):1189–93.
- Ritting AW, O'Malley MP, Rodner CM. Acute paronychia. *J Hand Surg Am.* 2012;37(5):1068–70.
- Bolton H, Fowler PJ, Jepson RP. Natural history and treatment of pulp space infection and osteomyelitis of the terminal phalanx. *J Bone Joint Surg Br.* 1949;31B:499–504.
- Zook EG. Anatomy and physiology of the perionychium. *Clin Anat.* 2003;16(1):1–8.
- Turkmen A, Warnter R, Page R. Digital pressure test for paronychia. *Br J Plast Surg.* 2004;57(1):93–4.
- Canales F, Newmeyer WI, Kilgore EJ. The treatment of felons and paronychias. *Hand Clin.* 1989;5(4):515–23.
- Santos Junior EP, Batista RRAM, Almeida ATF, Abreu RAA. Acidente de trabalho com material perfurocortante envolvendo profissionais e estudantes da área da saúde em hospital de referência. *Rev Bras Med Trab.* 2015;13(2):69–75.
- The National Institute for Occupational Safety and Health (NIOSH). Workplace Safety and Health Topics. Date unknown. <https://www.cdc.gov/niosh/topics/healthcare/default.html>
- Franko OI, Abrams RA. Hand infections. *Orthop Clin North Am.* 2013;44(4):625–34.
- Ware J. Sub-ungual malignant melanoma presenting as sub-acute paronychia following trauma. *Hand.* 2010;9(1):49–51.
- Rockwell P. Acute and chronic paronychia. *Am Fam Physician.* 2001;63:1113–36.
- Rigopoulos D, Larios G, Gregoriou S, et al. Acute and chronic paronychia. *Am Fam Physician.* 2008;77(3):339–46.
- Daniel CI. Paronychia. *Dermatol Clin.* 1985;3(3):461–4.
- Carpenter S, Rohde RS. Treatment of phalangeal fractures. *Hand Clin.* 2013;29(4):519–534.
- Wollina U. Acute paronychia: Comparative treatment with topical antibiotic alone or in combination with corticosteroid. *J Eur Acad Dermatol Venereol.* 2001;15(1):82–4.
- Tosti R, Ilyas A. Empiric antibiotics for acute infections of the hand. *J Hand Surg Am.* 2010;35(1):125–8.
- Shafritz A, Coppage J. Acute and chronic paronychia of the hand. *J Am Acad Orthop Surg.* 2014;22(3):165–74.